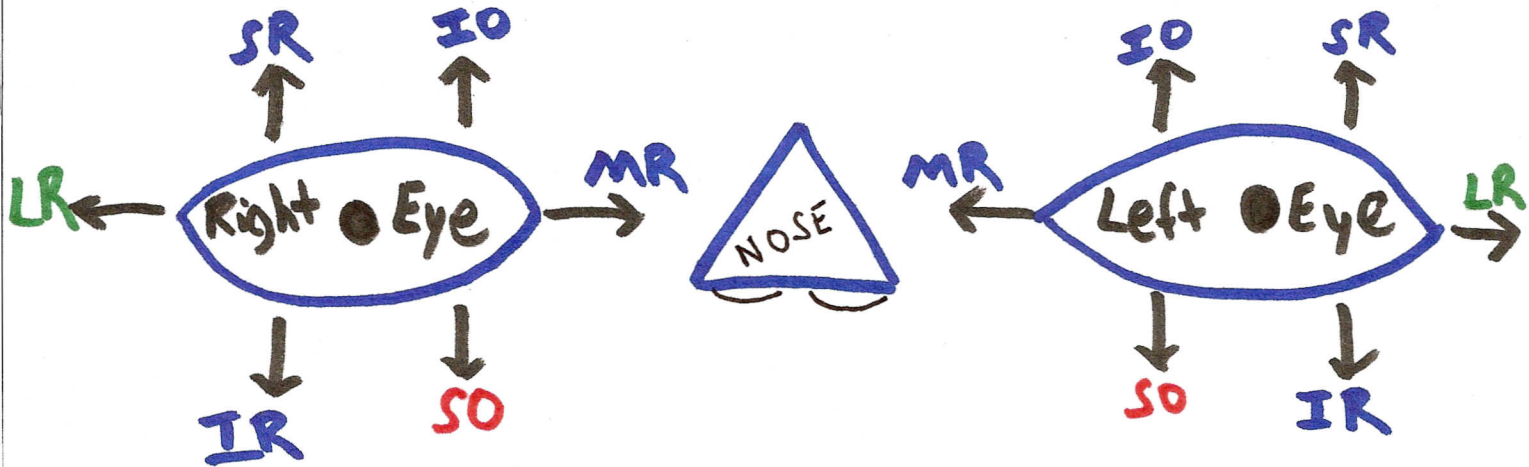


THE EXTRAOCULAR MUSCLES

as tested clinically...

by MedPod101.com



CRANIAL NERVE III

SR - superior rectus
IR - inferior rectus

IO - inferior oblique
MR - medial rectus

C.N. IV

SO - superior oblique

C.N. VI

LR - lateral rectus